

ASSOCIATION BETWEEN ANATOMICAL AND MORPHOLOGICAL FEATURES OF THE DENTAL ROOT AND PERIODONTAL DISEASE: A COMPREHENSIVE REVIEW

АСОЦИЈАЦИЈА ПОМЕЃУ АНАТОМСКО - МОРФОЛОШКИТЕ КАРАКТЕРИСТИКИ НА КОРЕНОТ НА ЗАБОТ И ПАРОДОНТАЛНАТА БОЛЕСТ: РЕВИЈАЛЕН ПРЕГЛЕД

Dollaku Shkreta B.¹, Popovska M.², Georgievska Jancheska T.³

¹Faculty of Medicine, University of Prishtina, Republic of Kosovo, ²USKC "St. Pantalejmon", Skopje, Republic of North Macedonia, ³Center for Rehabilitation of Verbal Communication Pathology, Faculty of Medicine, Ss. Cyril and Methodius University in Skopje, Republic of North Macedonia

Abstract

Introduction. Periodontal disease, as a chronic inflammatory condition affecting the tissues surrounding the teeth, is a major health concern. Various factors contribute to the development and progression of periodontal disease, including genetic component, environmental factors, and specific anatomical and morphological characteristics of the dental root. **Aim:** To record the risk factors associated with periodontal disease focusing on the anatomical and morphological characteristics of dental roots. **Material and method:** A systematic search of databases including PubMed, Scopus and Google Scholar was conducted to identify relevant studies published up to March 2024. The keywords used in search term were "root morphology", "root concavities", "root grooves", "root proximity", "furcation anatomy" and "periodontal disease". Selection criteria included English-language studies that provided quantitative or qualitative data on the impact of morphological variation on periodontal health. **Results:** By reviewing the current literature and numerous empirical studies, this paper elucidates how these anatomical factors contribute to the progression of periodontal disease and discusses the implications in clinical practice, emphasizing the need for tailored preventive and therapeutic approaches based on individual anatomical conditions. **Conclusion:** The anatomical and morphological characteristics of the dental root are crucial in the diagnosis and management of periodontal disease. These features not only affect how the disease starts and progresses, but impact the success of periodontal treatments as well. Dental professionals need to consider these factors in their clinical practice in order to personalize prevention and treatment plans effectively. This can lead to better periodontal health outcomes and help preserve patients' teeth. **Keywords:** periodontal disease, root morphology, root concavity, developmental grooves, root proximity.

Апстракт

Вовед: Пародонталната болест како една хронична воспалителна состојба во која се афектираниткивата околу забите е голем здравствен проблем. Различни фактори придонесуваат за развој и прогресија на пародонталната болест, вклучувајќи ја генетската компонента, факторите од околината и специфичните анатомски и морфолошки карактеристики на коренот на забот. **Цел:** Да се евидентираат факторите на ризик поврзани со пародонталната болест, фокусирајќи се на анатомските и морфолошките карактеристики на корените на забите. **Материјал и метод:** Спроведено е систематско пребарување на бази на податоци, вклучувајќи ги PubMed, Scopus и Google Scholar со цел да се идентификуваат релевантни студии објавени заклучно со март 2024 година. Клучните зборови користени во пребарувањето беа „морфологија на коренот“, „вдлабнатини на корените“, „конкавитети на корените“, „блискост на корените“, „фуркациона анатомија“ и „пародонтална болест“. Критериумите за избор вклучуваа студии на англиски јазик кои обезбедија квантитативни или квалитативни податоци за влијанието на морфолошките варијации на пародонталното здравје. **Резултати:** Со преглед на тековната литература и бројни емпириски студии, овој труд разјаснува како овие анатомски фактори придонесуваат за прогресијата на пародонталната болест и ги дискутира импликациите во клиничката пракса, истакнувајќи ја потребата за прилагодени превентивни и терапевтски пристапи базирани на индивидуални анатомски состојби. **Клучни зборови:** пародонтална болест, морфологија на корен, конкавитет на корен, развојни вдлабнатини, близина на корени.

Introduction

Periodontitis is a chronic multifactorial inflammatory disease associated with dysbiotic plaque biofilms which are the cause of progressive destruction of the tooth-supporting structures that may lead to tooth loss¹.

Considering that periodontitis is the most prevalent chronic inflammation in humans², severe periodontitis is also the sixth most prevalent disease of mankind³ and an important dental public health problem⁴. Approximately 10% of the global adult population is highly vulnerable to severe periodontitis, and 10–15% appears to be completely resistant to it, while the remainder varies between these two situations¹. The prevalence and rate of destruction increase gradually with age, showing a steep increase between the 3rd and the 4th decade of life¹.

The etiopathogenesis of periodontitis involves the complex interplay between pathogenic microorganisms in dental plaque and the immune response of the host, leading to destruction of the supporting tissues of the teeth². While bacterial plaque is the primary etiological factor, the susceptibility and severity of periodontal disease can be exacerbated by various other factors, including genetic predisposition, systemic conditions, environmental factors and specific anatomical features of teeth (Table 1). Among these, inherent anatomical and morphological factors of the dental root play a critical role in disease progression by affecting plaque accumulation and complicating oral hygiene efforts. This

review aims to elucidate the impact of these anatomical risk factors on periodontal health, drawing on a wide range of empirical studies to provide a comprehensive overview.

Material and method

A systematic search of databases including PubMed, Scopus, and Google Scholar was conducted to identify relevant studies published up to March 2024. Keywords used in the search included "root morphology," "root concavities," "root grooves," "root proximity," "furcation anatomy" and "periodontal disease." The selection criteria included studies in English that provided quantitative or qualitative data on the impact of root morphological variations on periodontal health. Due to the nature of the topic, a systematic review cannot be performed and the evidence is presented in a narrative format.

Results

Several tooth-related anatomical and morphological features associated to periodontal disease have been identified in literature (Table 2). For instructive purposes we have classified them in three major categories: root morphology (which includes morphological features of the root such as root abnormality in terms of shape, width and length; root concavities; radicular grooves and furcation anatomy), root surface aberrations (which includes enamel cervical projections and enamel pearls) and root proximity.

Table 1. Determinants of clinical periodontal health (Lang & Bartold, 2018)⁵

| |
|--|
| Microbiological Determinants of Clinical Periodontal Health |
| Supragingival plaque composition |
| Subgingival biofilm composition |
| Host Determinants of Clinical Periodontal Health |
| 1. Local predisposing factors |
| 1.1. Periodontal pockets |
| 1.2. Dental restorations |
| 1.3. Root anatomy |
| 1.4. Tooth position and crowding |
| 2. Systemic modifying factors |
| 2.1. Host immune function |
| 2.2. Systemic health |
| 2.3. Genetics |
| Environmental Determinants of Clinical Periodontal Health |
| Smoking |
| Medications |
| Stress |
| Nutrition |

Table 2. Significant anatomic features of the teeth (Matthews & Tabesh, 2004)⁶

| Tooth | Anatomic feature (ref.) | Prevalence (ref.) |
|---------------------------------|--|--|
| Maxillary incisors | Palatal groove 98% all grooves found in lateral incisors | 0.79(5)-21% (51) |
| Maxillary first bicuspid | Root trunk length; averages 4-14.6 mm (57) Furcal concavity on palatal aspect of buccal root Mesial root concavities Furcation entrance diameter <0.75 mm | 62% (57) 100% (14) 57% (15) |
| Maxillary molars | Furcation entrance diameter <0.75 Root trunk length; averages Mesial: 3.5 mm (99) – 4.2 mm (15) Buccal: 4.0 (99) – 4.8 mm (15, 93) Distal: 3.3 (12) Cervical enamel projections | 63% (15) 32.6% (112) |
| Mandibular molars | Furcation entrance diameter <0.75 mm Root trunk length; averages Buccal: 2.4 mm (15) – 3.14 mm (70) Lingual: 2.5 mm (15) – 4.17 mm (70) Cervical enamel projections First molar Second molar Bifurcation ridges | 50% (15) 80.4% (52) 48.4% (52) 65,5% (52) -76% (18) |

a) Root Morphology

The dental root is a critical factor for the function, stability, and long-term retention of the tooth. There are several aspects of its morphology that have been shown in numerous studies. In relation to them, it has been proven that they influence the sensitivity and progression of periodontal disease. Such aspects include:

Root abnormality in terms of shape, width and length

A wide range of root shapes are commonly observed clinically. Meng et al.⁷ categorized the most common shapes into five types: cone-root (considered the golden standard); slender root; curved root; maladjusted proportion of crown and root; and syncretic root (Table 3).

In literature, a common association between root abnormality and aggressive periodontitis has been established. Several studies, especially in Chinese patients, have documented a higher presence of root abnormalities in patients with aggressive periodontitis than in patients with chronic periodontitis or gingivitis⁸⁻¹⁰.

Xu et al.⁸ found that the prevalence of root abnormality was higher in patients with aggressive periodontitis (14.3%) than in those with chronic periodontitis (5.0%) and periodontal healthy individuals (3.7%). In another study, Chung et al.¹⁰ analysed the periodontal attachment loss of each tooth according to root form. In the comparison between root shape abnormality and periodontal attachment loss regardless of tooth type, type V root shape was

Table 3. Root abnormality classification according to Meng, 2007[7]

| Type | Type of root | Description |
|------------|--|---------------------------------------|
| I | Cone root | Normal root |
| II | Slender root | Root morphology is too thin |
| III | Curved root | Root form is curved |
| IV | Maladjusted proportion of crown and root | Root form is abnormally short or long |
| V | Syncretic root | Two- or three-root fusion |

associated with the highest periodontal attachment loss at 6.09 ± 2.11 ($P=0.01$).

Luet al.⁹ proved that abnormal root shape is an adverse prognostic factor in patients with aggressive periodontitis; they found that during the periodontal support therapy, patients with > 4 teeth with root abnormalities had a higher risk of tooth loss ($OR=3.52$, 95% CI 1.06–11.76, $P=0.035$).

While most studies in the past have been carried out on extracted teeth, the advent of the cone-beam computed tomography, with its multiple advantages in comparison to conventional dental radiology techniques, has made it possible to investigate in vivo the anatomical and morphological peculiarities of the dental root and their contribution in the onset and progression of periodontal disease. A very recent CBCT-based study by Aykol-Sahin et al.¹¹ examined the association between periodontal disease and root length and taper in single-rooted teeth. In this study, root length was identified as a potential protective parameter, as the risk of being diagnosed with periodontitis decreases when root length increases by 0.785 times ($p = 0.043$). Short root, and increased root-taper at specific teeth, were found to be important risk indicators for periodontitis.

Periodontal support is largely dependent on the surface of its attachment to the dental root.

Reduced root surface attachment area due to a congenital abnormality or disease process may compromise periodontal support. Different authors have argued that conditions such as short roots, conical roots, and syncretic roots have relatively minor surface areas of periodontal ligament compared to normally shaped roots; hence, overloading of such teeth may accelerate the process of periodontal destruction⁹. In addition, curved roots transfer adverse lateral force during physiological functioning (mastication); these lateral forces may lead to localized stress shielding and accelerated breakdown of the periodontal ligament. Mathematically, in experiencing the same amount of bone destruction, short roots lose higher proportions of periodontal support than long roots (Figure 1).

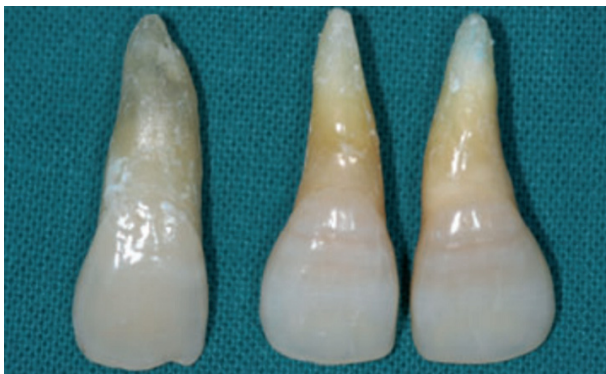

Figure 1. Comparison of normal and abnormal root shape, Meng et al., 2000⁷

Root concavities

Root concavities are another morphological feature of the dental root that is associated with periodontal disease. Root concavities can vary from shallow flutings to deep depressions. Typically, they are present in the proximal surfaces of the roots of the maxillary first premolars and mandibular incisors, the mesiobuccal root of the maxillary first molar and both roots of mandibular first molars. These concavities are wider in the maxillary than the mandibular teeth and since they are exposed early in the destructive disease process, they can create niches that accumulate plaque and calculus, thereby hindering effective cleaning either by the patient or by the dentist.

According to the position of root concavities, Ong and Neo¹² classified them into five groups: Type I: no concavity on the root; Type II: concavity starting at the enamel; Type III: concavity starting at the cemento-enamel junction; Type IV: concavity starting at the cervical third; Type V: concavity starting at the apical third (Figure 2).

Many authors have reported the incidence of root concavities in different teeth, an incidence that varies between studies, not only due to the genetic diversities of the studied population, but also because of the fact that previously, such morphological peculiarities were studied in extracted teeth, whereas now, with the use of CBCT technology, they can be studied in vivo. According to Fan et al.¹⁴, there is a high prevalence of mesial cervical concavity among maxillary first premolars (64.5% in single-root maxillary first premolars and 73.8% in two-root maxillary first premolars) with an increase of its prevalence and degree of concavity with the increase of the number of roots.

Research indicates that root concavities are associated with increased risk of periodontal disease. Using three-dimensional reconstruction by cone beam computed tomography, Zhao et al.¹³ investigated the influence of first premolar root concavity on clinical indices of chronic periodontal disease and alveolar bone defect, demonstrating a significantly higher mean probing depth and clinical attachment loss in first premolars with root concavities compared with those without concavity. Moreover, in the same study, significantly different types of alveolar bone defects and plaque accumulation were observed when comparing first premolars with concavities and those without a concavity. The study concluded that root concavities may be important in contributing to local periodontal disease of the first premolars.

Bhavya et al.¹⁵ conducted a similar study that evaluated the correlation between the root concavities in premolars and mandibular molars with chronic periodontitis. They also drew the conclusion that the association between root concavities of premolars and mandibular molars and periodontal disease could be rather more significant than had

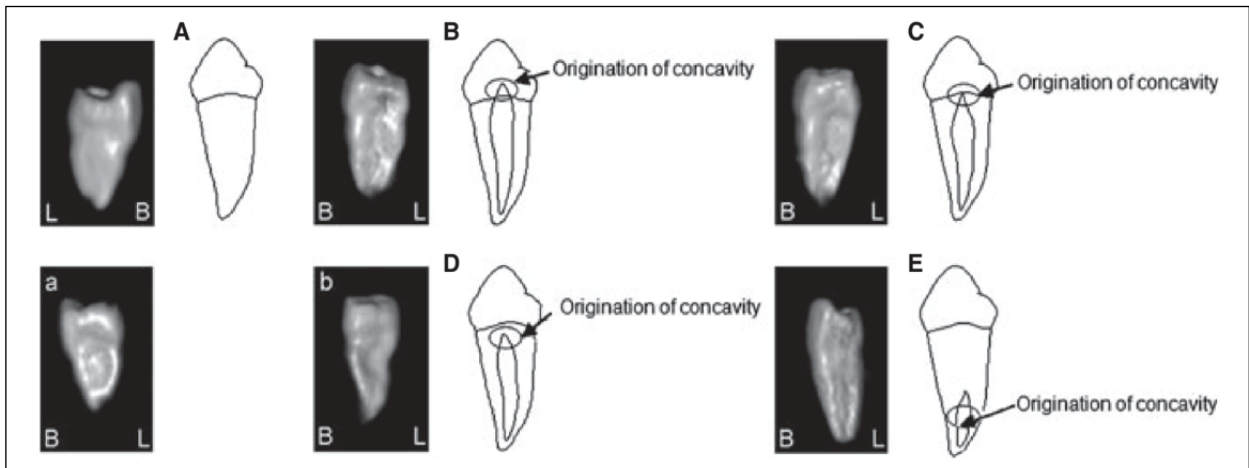


Figure 2. Three-dimensional reconstructions of root concavities from CBCT images of first maxillary premolars, representing the 5 types of root concavities according to Ong's classification and Zhao et al. 2014^{12,13}.

been previously thought. Similarly, evaluating in CBCT reconstructions, the relationship between mesial concavity of the maxillary premolars and their clinical indices of chronic periodontitis, Chen et al.¹⁶ concluded that root concavities may be important contributing factors to the localized periodontal disease of the first premolars.

a) Rad3icular grooves

The radicular groove is a developmental anomaly in which an infolding of the inner enamel epithelium and Hertwig's epithelial root sheath creates a groove that passes from the cingulum of the maxillary incisors apically onto the root. Root grooves are most commonly found in maxillary incisors-with a higher incidence in maxillary lateral incisors and can vary in depth and length (Figure 3). They can be found on the buccal or

lingual/palatal side, located either mesially, centrally or distally. The prevalence of radicular grooves, described in previous studies, ranges from approximately 2 to 10% for palatal, and from 4 to 5% for buccal grooves¹⁷⁻²¹. The differences in prevalence among studies could be attributed to disparate study methodologies and/or found in genetic diversities between the examined populations.

Type I: short groove (not beyond the coronal third of the root). Type II: long and shallow groove (beyond the coronal third of the root). Type III: long and deep groove (beyond the coronal third of the root), associated with complex root canal system - Alkhatany et al., 2022,²²

The presence of root grooves has been linked to localized periodontal destruction due to their role in harbouring plaque^{23,24}. Lee et al.²⁵ described eleven cases where unilateral and bilateral defects in lateral incisors were associated with moderate/severe periodontal disease. Another study²⁶

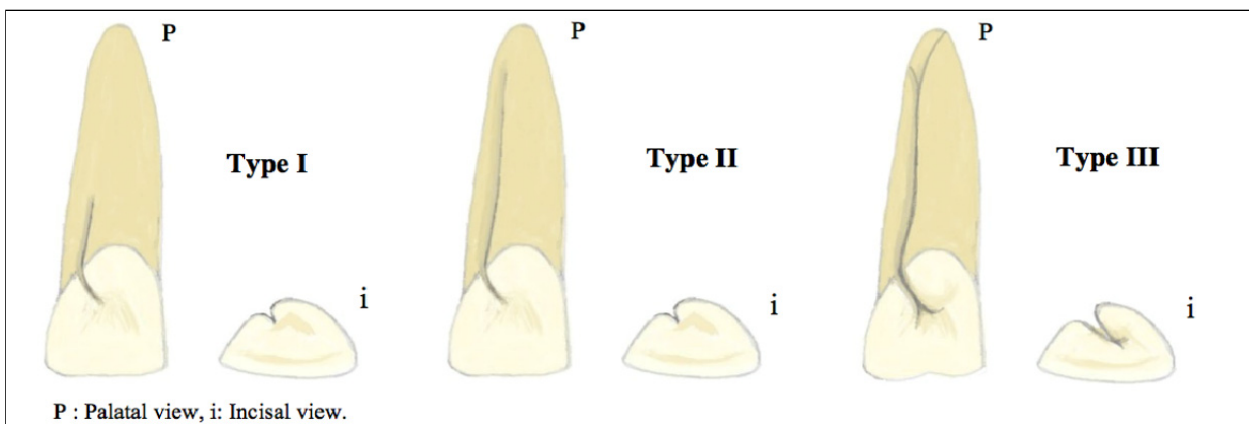


Figure 3. Gu's Classification based on the severity of the palatoradicular groove

examined the association between palatoradicular grooves and periodontal health by measuring the plaque index, bleeding index, and pocket depth in 552 maxillary lateral incisors in Saudi adults. They reported that teeth with an apical groove showed a plaque index and a bleeding index of 100%; thus, the apical extension of the groove was significantly associated with poor periodontal health.

In some cases, even the dental pulp may be affected, presenting the clinical manifestation of an endo-perio lesion that is the result of the combination of a primary periodontal lesion with secondary involvement of the pulp. This occurrence emphasizes the importance of correctly diagnosing and treating periodontal lesions associated with radicular grooves.

Furcation anatomy

Longitudinal studies have demonstrated that molar teeth, especially maxillary molars are the most affected by periodontitis, and that in these teeth the tooth survival rate is significantly related to the furcation involvement²⁷. In multiradicular teeth, the progression of periodontal disease is usually higher in furcation areas. Furcation involvement, a condition where periodontal disease affects the area between the roots of multiradicular teeth, poses a significant challenge in the management of periodontal disease. The complex anatomy of furcation areas, with limited access for instrumentation and plaque control, contributes to the rapid progression of periodontal destruction. Moreover, the presence of furcation involvement is associated with a higher risk of tooth loss and a less favourable response to periodontal treatment.

Several morphological factors such as root trunk length, furcation entrance and the anatomy in the prefurcation area have been evaluated morphometrically in existing literature^{28,29}.

The severity of furcation involvement is highly dependent on the relationship between the amount of attachment loss and the root trunk length, a parameter used to describe the distance from cemento-enamel junction to the furcation entrance. A short root trunk would result in an early development of furcation involvement, already at initial or moderate stages of breakdown of the attachment apparatus. Conversely, an apically located furcation would be more protected in the initial stages of marginal periodontitis³⁰. Similar findings were reported by Madi et al.³¹ who investigated, among other parameters, the length of the root trunk in the mandibular molars of periodontitis and non-periodontitis patients. This CBCT-based, cross-sectional study found that the first molars of non-periodontitis patients (4.65 ± 0.90) had significantly longer ($p=0.007$) root trunks than periodontitis patients (4.09 ± 1.02). Anyway, in spite of being more vulnerable to furcal involvement, molars with short root trunks have a better prognosis after

treatment, due to the fact that it is presumed that less periodontal destruction has occurred. In contrast, molars with a long root trunk and short roots may not be a candidate for root resection, since these teeth lose more periodontal support with furcal involvement³².

Another important factor that can influence the effectiveness of the furcation involvement therapy is also the diameter of the furcation entrance. Bower et al.³³ found that 81% of furcation entrances were $<1\text{mm}$, whereas 58% were $<0.75\text{mm}$, which means that in the majority of teeth, the furcation entrance is narrower than the width of the standard Gracey curette. Narrow furcation implies an increased difficulty of access, even in a surgical approach, through furcation entrances for complete root debridement - leading to a poor periodontal outcome. A similar conclusion was also drawn by Marcacciniet al.²⁸ in their morphometric study of the root anatomy in furcation area of mandibular first molars.

b) Root surface aberrations

Cervical enamel projections

Cervical enamel projections represent a dipping of the enamel from the cemento-enamel junction towards the furcation area of the molars (Figure 4). They are more prevalent in mandibular second molars than either in first mandibular or maxillary molars. Since a connective tissue attachment is not possible on the enamel, the presence of cervical enamel projections has been considered to be a contributory factor in furcation involvement.

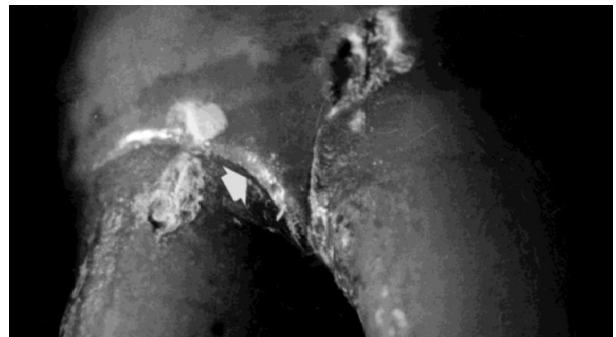


Figure 4. Second mandibular molar showing cervical enamel projection extending into the furcation on the buccal surface³⁰

Hou et Tsai³⁴ reported the prevalence of cervical enamel projections in molars with and without furcation involvement. 82.5% of molars cervical enamel projections exhibited furcation involvement, while this was true for 17.5% of molars that had no cervical enamel projections.

Enamel Pearls

Enamel pearls are less common than cervical enamel projections, with a mean incidence of 2.6% and a variation

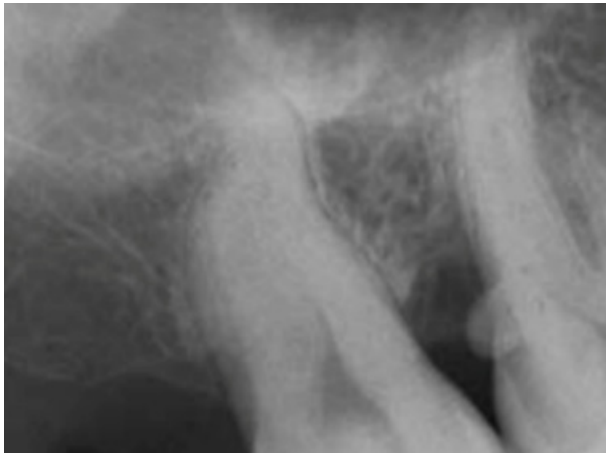


Figure 5. Radiographic presentation of an enamel pearl on a maxillary second molar resulting from periodontal destruction Matthews & Tabesh, 2004⁶

of 1.1% to 9.7% depending on tooth type and location, as found in a literature review³⁵. They are most commonly found in the maxillary third molar, with the mandibular third molars and maxillary second molars being the second most common position³⁶. One pearl per root is the most common occurrence, but two or more pearls have also been identified³⁶.

Various studies have found an association between enamel pearls and adjacent localized periodontal destruction^{6,36}. The presence of enamel pearls can affect mechanical control of dental biofilm, since they serve as niches which retain bacterial biofilm and dental calculus promoting the progression of periodontal disease (Figure 5).

c) Root proximity

Root proximity refers to the closeness of adjacent tooth roots, which can reduce the interdental space crucial for effective cleaning. According to Vermylet al.³⁷, it is a term used to describe the situation where there is 0.8 mm or less bone or interdental tissue present between the two involved roots, as measured radiographically. This anatomical feature is commonly observed in the posterior dentition of the maxilla between the first and the second molar, but also anteriorly, between the central and lateral incisor. In the mandible, it is more prevalent both between the central incisors and between the central and lateral incisor.

In a case-control study, Vermylet al.³⁸ compared on full mouth periapical radiographs the root proximity in patients with advanced periodontal disease and controls without periodontal disease. They found that root proximity was a very common occurrence in patients with advanced periodontal disease (with 94.4% of them having at least one interdental space with root proximity and 75% of them having severe root proximity), while not so com-

mon in patients without periodontal disease (with 64% of them having at least one interdental space with root proximity and only 30% having severe root proximity). Also, their study showed that a patient with bilateral root proximity has a 3.6 times higher risk of being affected by periodontitis, concluding that root proximity must be taken into consideration as a risk indicator for periodontal disease. Close root proximity can lead to interdental bone loss and furcation involvement. They reported that root proximity was a significant predictor of furcation involvement in lower molars, independent of other factors like overall plaque levels and smoking.

Recent CBCT-based studies³⁹, that evaluated the association between root proximity and periodontal disease both in the anterior and the posterior dentition, confirmed the findings of previous authors and concluded that root proximity could be considered an important risk indicator for periodontal disease.

Conclusions

Anatomical and morphological characteristics of the dental root are pivotal in the risk assessment and management of periodontal disease. These features not only influence the initiation and progression of the disease but also affect the efficacy of therapeutic interventions. Dental professionals must consider these factors in their comprehensive assessment to tailor prevention and treatment strategies effectively, thereby improving periodontal health outcomes and preserving the dentition. While the current literature provides valuable insights into the relationship between anatomical and morphological factors of the dental root and periodontal disease, further research is needed to fully understand the complex interactions between these variables. Future studies should focus on longitudinal investigations to assess the long-term impact of anatomical and morphological characteristics on periodontal health.

Reference

1. Tonetti MS, Greenwell H, Kornman KS. Staging and grading of periodontitis: Framework and proposal of a new classification and case definition. *Journal of periodontology* 2018; 89 Suppl 1: S159–S172.
2. Pihlstrom BL, Michalowicz BS, Johnson NW. Periodontal diseases. *Lancet (London, England)* 2005; 366(9499):1809–1820.
3. Kassebaum NJ, Bernabé E, Dahiya M, Bhandari B, Murray CJ, Marcenes W. Global burden of severe periodontitis in 1990–2010: a systematic review and meta-regression. *Journal of dental research* 2014; 93(11):1045–1053.
4. Eke PI, Dye BA, Wei L, Thornton-Evans GO, Genco RJ. CDC Periodontal Disease Surveillance workgroup: James Beck (University of North Carolina, Chapel Hill, USA), Gordon Douglass (Past President, American Academy of Periodontology), Roy Page (University of Washin.). Prevalence of periodontitis in adults in the United States: 2009 and 2010. *Journal of dental research* 2012; 91(10):914–920.

5. Lang N, Bartold P. Periodontal health. *Journal of Periodontology*2018; 89:S9-S16.
6. Matthews D, Tabesh M. Detection of localized tooth-related factors that predispose to periodontal infections. *Periodontology* 2000;2004; 34(1):136-150.
7. Meng H, Xu L, Li Q, Han J, Zhao Y. Determinants of host susceptibility in aggressive periodontitis. *Periodontology* 2000;2007; 43:133-159.
8. Xu L, Meng HX, Tian Y, Zhang L, Feng XH, Zhang G. Evaluation of root abnormality in patients with aggressive periodontitis. *Zhonghua Kou Qiang Yi Xue Za Zhi*2009; 44:266–69.
9. Lu D, Meng H, Xu L, Wang X, Zhang L, Tian Y. Root abnormalities and nonsurgical management of generalized aggressive periodontitis. *Journal of oral science*2017; 59(1):103-110.
10. Chung YM, Jeong SN. Analysis of periodontal attachment loss in relation to root form abnormalities. *Journal of periodontal & implant science*2013; 43(6): 276-282.
11. Aykol-Sahin G, Arsan B, Altan-Koran SM, Huck O, Baser U. Association between root taper and root proximity of single-rooted teeth with periodontitis: a cone-beam computed tomography based study. *Odontology*2022; 110(2):356–364.
12. Ong G, Neo J. A survey of approximal root concavities in an ethnic Chinese population. *Archives of oral biology*1990; 35(11):925–928.
13. Zhao H, Wang H, Pan Y, Pan C, Jin X. The relationship between root concavities in first premolars and chronic periodontitis. *Journal of periodontal research*2014; 49(2):213–219.
14. Fan L, Yuan K, Niu C, Ma R, Huang Z. A cone-beam computed tomography study of the mesial cervical concavity of maxillary first premolars. *Archives of oral biology*2018; 92:79-82.
15. Bhavya B, Shaji V. The Relationship Between Root Concavities in Premolars and Mandibular Molars and Chronic Periodontitis: A Tomographic Study. *International J., of Contemporary Medical Research* 2017; 4(8):1728–1732.
16. Chen F, Liu Q, Liu X, Fang Q, Zhou B, Li R, Shen Z, Zheng KX, Ding C, Zhong L. Periodontitis was associated with mesial concavity of the maxillary first premolar: a cross-sectional study. *Scientific reports*2024; 14(1): 2955.
17. Everett FG, Kramer GM. The disto-lingual groove in the maxillary lateral incisor; a periodontal hazard. *Journal of periodontology*1972; 43(6):352–361.
18. Kogon SL. The prevalence, location and conformation of palato-radicular grooves in maxillary incisors. *Journal of periodontology*1986; 57(4):231–234.
19. Mass E, Aharoni K, Vardimon AD. Labial-cervical-vertical groove in maxillary permanent incisors--prevalence, severity, and affected soft tissue. *Quintessence international*2005; 36(4):281–286.
20. Storrer CM, Sanchez PL, Romito GA, Pustiglioni FE. Morphometric study of length and grooves of maxillary lateral incisor roots. *Archives of oral biology*2006; 51(8):649–654.
21. Tan X, Zhang L, Zhou W, Li Y, Ning J, Chen X, Song D, Zhou X, Huang D. Palatal Radicular Groove Morphology of the Maxillary Incisors: A Case Series Report. *Journal of endodontics*2017; 43(5):827–833.
22. Alkahtany SM, Alrwais F, Altamimi A, Bukhary SM, Mirdad A. The incidence of radicular groove on maxillary lateral incisors of Saudi population: CBCT evaluation. *BMC oral health*2022; 22(1):583.
23. Kim H, Choi Y, Yu M, Lee K, Min K. Recognition and management of palatogingival groove for tooth survival: a literature review. *Restorative Dentistry & Endodontics*2017; 42(2):77-86.
24. Zhang R, Xiong J, Haapasalo M, Shen Y, Meng L. Palatogingival grooves associated with periodontal bone loss of maxillary incisors in a Chinese population. *Australian Endodontic Journal*2022; 48(2):313-321.
25. Lee KW, Lee EC, Poon KY. Palato-gingival grooves in maxillary incisors. A possible predisposing factor to localised periodontal disease. *British dental journal*1968; 124(1):14-8.
26. Al-Rasheed A. Relationship between palato-radicular groove and periodontal health in maxillary lateral incisors. *Pakistani Oral Dent Journal*2011; 31:54–157.
27. Perminio DJ, Rodrigues DM, Vianna KC, Machado A, Lopes R, Barboza EP. Micro-tomographic analysis of the root trunk and pre-furcation area of the first mandibular molars. *Odontology*2022; 110(1):120–126.
28. Marcaccini AM, Pavanelo A, Nogueira AV, Souza JA, Porciúncula HF, Cirelli JA. Morphometric study of the root anatomy in furcation area of mandibular first molars. *Journal of applied oral science: revista FOB*2012; 20(1):76–81.
29. Barboza CA, Jr Rodrigues DM, Petersen R, Trisão GC, Barboza EP. Biometric study of the pre-furcation area of human mandibular first molars. *The International journal of periodontics & restorative dentistry*2014; 34(6): 857–861.
30. Roussa, E. Anatomic characteristics of the furcation and root surfaces of molar teeth and their significance in the clinical management of marginal periodontitis. *Clinical Anatomy*1998; 11(3):177-186.
31. Madi M, Elakel A, Aly N, Al Mansour R, Al Mansour A, Zakaria O. Assessment of Mandibular Molar Root Morphology Using Cone Beam Computed Tomography in Periodontitis Patients from Eastern Province: A Cross-Sectional Study. *Cureus*2021; 13(12): e20804.
32. Al-Shammari K, Kazor C, Wang H. Molar root anatomy and management of furcation defects. *Journal of Clinical Periodontology*2001; 28(8):730-740.
33. Bower RC. Furcation morphology relative to periodontal treatment. Furcation entrance architecture. *Journal of periodontology*1979; 50(1): 23–27.
34. Hou GL, Tsai CC. Cervical enamel projection and intermediate bifurcational ridge correlated with molar furcation involvements. *Journal of periodontology*1997; 68(7):687-693.
35. Moskow BS, Canut PM. Studies on root enamel (2). Enamel pearls. A review of their morphology, localization, nomenclature, occurrence, classification, histogenesis and incidence. *Journal of clinical periodontology*1990; 17(5): 275–281.
36. Chrcanovic BR, Abreu MH, Custódio AL. Prevalence of enamel pearls in teeth from a human teeth bank. *Journal of oral science*2010; 52(2): 257–260.
37. Vermynen K, De Quincey G, Van't Hof M, Wolffe G, Renggli H. Classification, reproducibility and prevalence of root proximity in periodontal patients. *Journal of Clinical Periodontology*2005; 32(3):254-259.
38. Vermynen K, De Quincey G, Wolffe G, Van 't Hof M, Renggli H. Root proximity as a risk marker for periodontal disease: a case-control study. *Journal of Clinical Periodontology*2005; 32(3):260-265.
39. Aykol-Sahin G, Arsan B. Furcation area and root proximity of molars as a risk indicator of periodontitis: a cone beam computed tomography-based study. *Oral radiology*2023; 39(4):802-810.