

A-PRF AS A SOLO GRAFT MATERIAL IN SOCKET PRESERVATION

A-PRF КАКО САМОСТОЕН ГРАФТ МАТЕРИЈАЛ ВО ПРЕЗЕРВАЦИЈА НА ПОСТЕКСТРАКЦИОНА АЛВЕОЛА

Trajculeski S.¹, Veleska Stevkovska D.¹, Terzievska A.¹, Gigovska Arsova A.¹, Lazov K.², Spirov V.¹

¹University Dental Clinical Center "St. Pantelejmon" - Skopje, Republic of North Macedonia, Department of Oral Surgery and Implantology, ²Institute for Transfusiology –Skopje, Republic of North Macedonia

Abstract

Introduction: The changes in residual alveolar ridge dimensions are a time-dependent process following tooth extraction. To maintain the width and height of residual alveolar ridge, various bone grafts, substitutes or biomaterials are utilized. A-PRF, as an autologous blood derivative, is employed because of its histomorphometric composition, which includes a dense fibrin mesh with a number of platelets. These properties make it suitable for achieving the desired outcomes in this context. **Aim:** The utilization of A-PRF in socket preservation, dimensional changes and bone density in newly formed bone. **Case report:** A patient with indication of tooth extraction, followed by socket preservation using solo PRF as a graft material. Analysis of changes in the width and height dimensions of the alveoli, also as well as an assessment of bone density of de novo formed bone in the socket. **Conclusion:** Recommendation to use A-PRF as an autologous blood derivative for socket preservation procedures. **Key words:** A-PRF, CBCT, GBR, socket preservation.

Апстракт

Вовед: Димензионалните промени на резидуалниот алвеоларен гребен после екстракцијата на забите се временски зависен процес. Во цел на сочуввање на висината и ширината на резидуалниот алвеоларен гребен се користат коскени графтови, супституенти и биоматеријали. А- PRF како автологен крвен дериват се користи заради неговиот хистоморфометриски состав на густа мрежа на фибрински влакна во кои се заробени голем број на тромбоцити и неговите својства. **Цел:** Употребата на А-PRF за презервација на алвеола, димензионални промени и густина на новосоздадена коска. **Приказ на случај:** Пациент со индикација за екстракција на заб, и понатамошна презервација на алвеола со самостоен PRF чеп. Анализа на параметрите на ширина и висина на постекстракционата алвеола, како и густината на новосоздадената коска преку CBCT анализа. **Заклучок:** А-PRF се препорачува за презервација на алвеола како автологен крвен дериват. **Клучни зборови:** А-PRF, CBCT, GBR, презервација на алвеола.

Introduction

After tooth extraction, the wound healing process commences, culminating in the phases of bone modeling and remodeling, involving bone apposition and resorption¹.

The most significant resorption of the residual alveolar ridge occurs within the first six months following the tooth extraction, predominantly in the vestibulo-oral direction. The dimensional changes are time-dependent and persist throughout an individual's lifetime².

Preserving the volume of residual alveolar ridge is crucial for successful esthetic and functional teeth rehabilitation. This is accomplished through techniques such as Guided Bone Regeneration (GBR) and Guided Tissue Regeneration (GTR), Socket Preservation (SP) a com-

ponent of Alveolar Ridge Preservation (ARP), and Alveolar Ridge Augmentation (ARA) are part of the GBR technique. Socket preservation is recommended as an economical and reliable method^{3,4}.

Many bone grafts, bone substitutes and biomaterials are utilized in the field of oral surgery and implantology as a part of GBR techniques. These materials are categorized based on their origin, including autografts, allografts, xenografts and alloplastic materials, each with its own advantages and disadvantages. Autografts, known for their osteogenic potentials, or activity, are considered the gold standard in GBR procedures⁵.

Platelet Rich Fibrin (PRF), invented by Dr. Joseph Choukroun in 2001, represents the second generation of autologous blood derivatives. This method involves the simple and cost-effective process of performing the fib-

rin clot solely through centrifugation, without the need for anticoagulants⁶.

Upon completion of the centrifugation process, in specially designed A-PRF tubes, three layers are formed: the upper layer of Platelet Poor Plasma (PPP), the Fibrin clot (FC) and the Erythrocyte sediment (ES)⁷.

Histomorphologically, the PRF clot appears as a mesh of dense fibrin fibers containing numerous platelets and erythrocytes. Upon degranulation of platelet, plasma proteins, pro and anti-inflammatory cytokines (IL-1, IL-4, IL-6 and IL-8) and Growth Factors-GF (VEGF, PDGF, ILF, FGF) are released. These components have an active participation in the inflammatory response, neoangiogenesis, neoosteogenesis and neocolagenogenesis, thereby influencing post-operative morbidity⁸.

Due to its beneficial properties PRF has been widely used in many indications of oral and maxillofacial surgery over the last decade⁹. The aim of this case report is to evaluate the benefits of using A-PRF as a solo graft material for socket preservation.

Case report

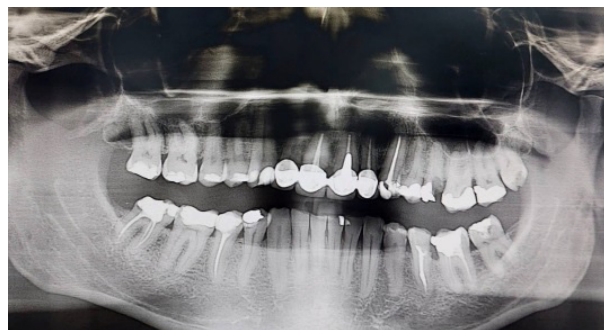A 47-year-old healthy patient, identified as TG, visited our clinic with a fractured irreparable root of tooth 25. During the examination, he complained of pain in the affected tooth, and denied any other relevant medical conditions. Clinical examination revealed erythema of the mucosa in the area near the apex of the tooth, pain on vertical percussion and pain on palpation in the maxillary vestibule corresponding to the root apex. An orthopantomogram was performed, which showed a residual gangrenous root with periapical changes, along with diffuse chronic periodontitis (Picture 1). After conservative treatment involving pulp extirpation and drainage, the local symptoms of acute odontogenic infection were relieved. A root extraction and socket preservation was recommended, followed by implant-prosthetic or prosthetic rehabilitation.

The patient was informed about the oral-surgical procedure and has signed informed consent form in accordance with the Helsinki Declaration of 1975, revised in 2013 for the implementation of the intervention.

Surgical tooth extraction was performed based on asepsis and antisepsis principles.

One hour before the intervention, a single dose of antibiotic prophylaxis with Amoxicillin plus clavulanic acid 2g was administrated. Venous blood was collected from the patient's cubital veins using the Vacutainer method, with 10 ml of blood collected in A-PRF tubes. The APRF tubes were then placed in a centrifuge

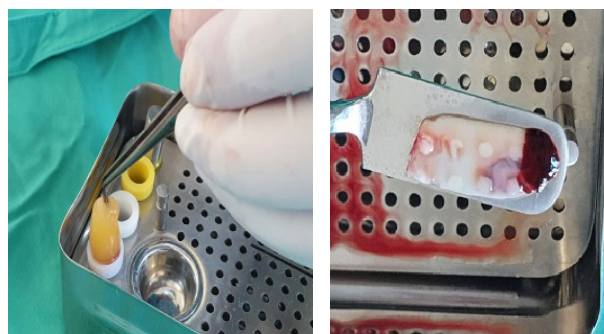
(Biobase LC-H4K centrifuge, BIOBASE, Jinjan, Guangdong, China), using the A-PRF+ protocol on 1300 rpm/8 min (Picture 2).



Picture 1. Orthopantomography



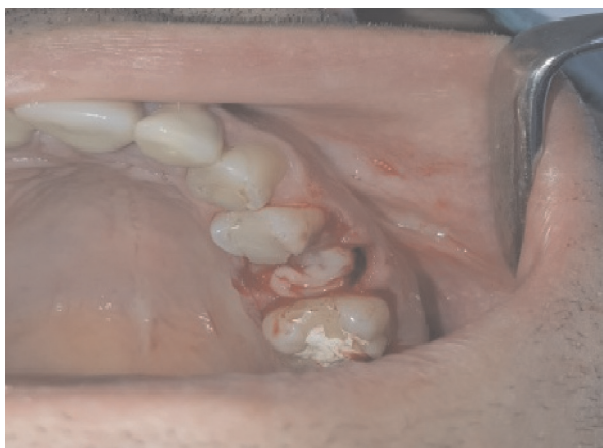Picture 2. A-PRF tubes



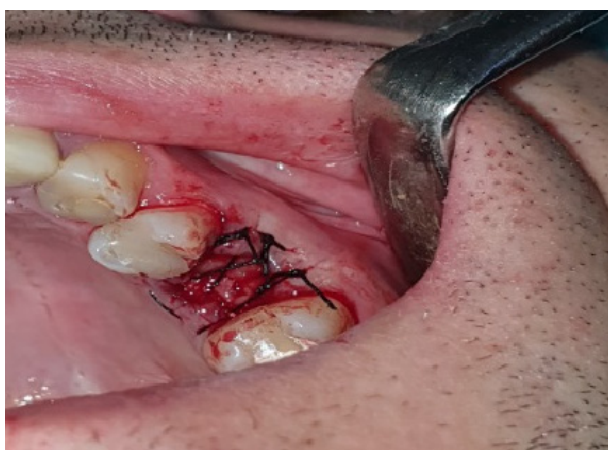Picture 3. PRF plug and membrane

Terminal anesthesia was applied using 2% mepivacaine with 1:100000 epinephrine. Atraumatic root extraction was performed, followed by surgical wound debridement, through irrigation with NaCl 0.9%.

The PRF clot, obtained from the centrifuged A-PRF tubes, was collected and the erythrocyte sediment was gently removed. Using a specially designed PRF box, a PRF plug was created from the first PRF clot, and a PRF membrane was obtained from the second PRF clot (Picture 3).

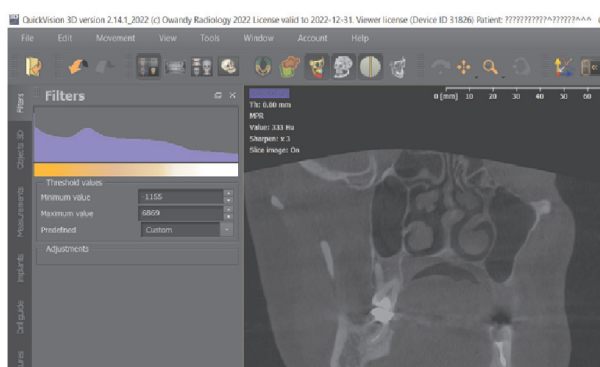


Picture 4. PRF plug and membrane application



Picture 5. Stabilization suture

The PRF plug was gently placed in the socket using a PRF plugger, followed by the application of the PRF membrane. Finally, a stabilizing suture was applied (Picture 4).



Picture 6. Bone density - CBCT

Immediately after the surgical intervention, clinical measurements were obtained to assess the horizontal dimension (socket width) using a bone measurement caliper. The vertical dimension was measured from the cement-enamel junction (CEJ) of the neighboring tooth to the edge of the interdental septa. The same measurements were repeated four months after the surgical treatment. The recorded data are presented in Table 1.

After the surgery, post-operative morbidity was evaluated by assessing the presence or absence of pain, swelling, hematoma, trismus, infection, loss of function, lymphadenitis and the use of pain killers.

Four months after the surgery, the bone density of the newly formed bone was evaluated in the post extraction socket and local periapical area using CBCT 3D imaging. The bone density was measured in Hounsfield Units (HU) (Picture 6), and the data are presented in Table 1.

The measured bone density in our case falls under D3 class (350-850HU) according to the classification by Misch10. The classification indicates thin, porous cortical bone on crest and fine trabecular bone within, which is considered to be the most suitable bone quality for implant placement.

Table 1. Clinical and CBCT measurements

	IMMEDIATE POSTOPERATIVE (mm)	FOUR MONTHS POSTOPERATIVE (mm)
HORISONTAL DIMENSION	15	12.5
VERTICAL DIMENSION	3	3
PAPILA HEIGHT	1	1
BONE DENSITY SOCKET	/	441 HU
PERIAPICAL BONE DENSITY	/	521 HU

Discussion

Maintaining an adequate volume of the alveolar ridge is essential for the successful placement of dental implants. Alveolar ridge preservation includes several techniques aimed at reducing the dimensional changes in both hard and soft tissues following tooth extraction. However, the high costs often limit the use of biomaterials. Moreover, the exposure of resorbable or non-resorbable membranes, often used in combination with bone substitutes, could compromise bone regeneration and impede wound healing.

A-PRF is an autologous blood derivative with a three and tetra molecular structure of fibrin mesh, facilitating the prolonged release of cytokines and growth factors. PRF effectively stabilizes blood clots in post-extraction wounds. Through its mechanism of action, it promotes the proliferation, migration and differentiation of mesenchymal stem cells, fostering neoangiogenesis, neostemogenesis and neocollagenogenesis, thus resulting in faster and improved wound healing¹¹.

The systematic review conducted by Enferest Dohan et al., describes the slow release of growth factors in PRF compared to the first generation of blood derives, specifically PRP. PRF exhibits a significantly slower release of growth factors and plasma proteins, leading to improved wound healing. Additionally, PRP membranes dissolve in five days, whereas PRF membranes remain intact for seven days¹².

Our clinical measurements of the immediate post-extraction socket and four-month follow-up showed a decrease in the intensity of residual alveolar ridge bone loss, which aligns with findings reported in the literature¹³.

In the systematic review conducted by Castro et al., a total of 14 articles were included and analyzed. Three subgroups were created based on the application of the techniques: sinus floor elevation (SFE), alveolar ridge preservation and implant therapy. In the subgroup focusing on alveolar ridge preservation, the collected data indicated a significantly slower bone resorption in both horizontal and vertical dimensions of preserved residual alveolar ridge¹⁴.

The evaluation of postoperative morbidity revealed the absence of postoperative sequelae, and the period of postoperative rehabilitation is shortened^{15,16}.

Improved neo-osteogenesis and architectural integrity of the de novo formed bone is evident through CBCT analysis^{17,18}.

The results of this report are consistent with previous studies¹⁹ where PRF showed to be effective in preserving both hard and soft tissues without interfering with physiological bone healing process. Ridge preservation tech-

niques are highly desirable when functional and aesthetic results are demanded. Moreover, such procedures also facilitate implant placement because of the beneficial effects of PRF in reducing dimensional changes in the post-extraction socket.

Considering the limitations of this report, our results support the utilization of A-PRF in alveolar ridge preservation when implant placement is scheduled following tooth extraction. However, additional larger-scale studies with randomized design are necessary to confirm our findings and investigate possible specific indications of A-PRF compared to other biomaterials.

Conclusion

Based on the obtained results of this study, A-PRF can be recommended as an economical autologous blood derivative for socket preservation methods.

Reference

1. Araújo MG, Silva CO, Misawa M, Sukekava F. Alveolar socket healing: what can we learn? *Periodontol* 2000. 2015 Jun; 68(1):122-34. doi: 10.1111/prd.12082. PMID: 25867983.
2. Araújo MG, Lindhe J. Dimensional ridge alterations following tooth extraction. An experimental study in the dog. *J Clin Periodontol*. 2005 Feb; 32(2):212-8. doi: 10.1111/j.1600-051X.2005.00642.x. PMID: 15691354
3. McAllister BS, Haghighat K. Bone augmentation techniques. *J Periodontol*. 2007 Mar;78(3):377-96. doi: 10.1902/jop.2007.060048. PMID: 17335361.
4. Hämmerle CH, Araújo MG, Simion M; Osteology Consensus Group 2011. Evidence-based knowledge on the biology and treatment of extraction sockets. *Clin Oral Implants Res*. 2012 Feb;23 Suppl 5:80-2. doi: 10.1111/j.1600-0501.2011.02370.x. Erratum in: *Clin Oral Implants Res*. 2012 May;23(5):641. PMID: 22211307.
5. Miron R J, Hedbom N, Saulacic Y et al. Osteogenic Potential of Autogenous Bone Grafts Harvested with Four Different Surgical Techniques. *J Dent Res* 2011 90: 1428
6. Choukroun J, Adda F, Schoeffler C, Vervelle A. The PRF: an opportunity in implantology. *Implantodontie*. 2001;42:55-62.
7. Marx RE. Platelet-rich plasma: evidence to support its use. *J Oral Maxillofac Surg*. 2004;62:489-496
8. Dohan DM, Choukroun J, Diss A, Dohan SL, Dohan AJ, Mouhyi J, Gogly B. Platelet-rich fibrin (PRF): a second-generation platelet concentrate. Part II: platelet-related biologic features. *Oral Surg Oral Med Oral Pathol Oral Radiol Endod*. 2006 Mar;101(3):e45-50. doi: 10.1016/j.tripleo.2005.07.009. Epub 2006 Jan 10. PMID: 16504850.
9. Al-Hamed FS, Mahri M, Al-Waeli H, Torres J, Badran Z and Tamimi F (2019) Regenerative Effect of Platelet Concentrates in Oral and Craniofacial Regeneration. *Front. Cardiovasc. Med*. 6:126. doi: 10.3389/fcvm.2019.00126
10. Misch CE. *Contemporary Implant Dentistry-E-Book*. St. Louis: Elsevier Health Sciences; 2007
11. Dolati S, Yousefi M, Pishgahi A, Nourbakhsh S, Pourabbas B, Shakouri SK. Prospects for the application of growth factors in wound healing. *Growth Factors*. 2020 Jan;38(1):25-34. doi: 10.1080/08977194.2020.1820499. Epub 2020 Nov 5. PMID: 33148072.

-
12. Dohan Ehrenfest DM, Bielecki T, Jimbo R, Barbé G, Del Corso M, Inchingolo F, Sammartino G. Do the fibrin architecture and leukocyte content influence the growth factor release of platelet concentrates? An evidence-based answer comparing a pure platelet-rich plasma (P-PRP) gel and a leukocyte- and platelet-rich fibrin (L-PRF). *Curr Pharm Biotechnol*. 2012 Jun;13(7):1145-52. doi: 10.2174/138920112800624382. PMID: 21740377.
 13. Schropp L, Wenzel A, Kostopoulos L, Karring T. Bone healing and soft tissue contour changes following single-tooth extraction: a clinical and radiographic 12-month prospective study. *Int J Periodontics Restorative Dent*. 2003 Aug;23(4):313-23. PMID: 12956475
 14. Castro AB, Meschi N, Temmerman A, Pinto N, Lambrechts P, Teughels W, Quirynen M. Regenerative potential of leucocyte- and platelet-rich fibrin. Part B: sinus floor elevation, alveolar ridge preservation and implant therapy. A systematic review. *J Clin Periodontol*. 2017 Feb;44(2):225-234. doi: 10.1111/jcpe.12658. Epub 2017 Jan 10. PMID: 27891638; PMCID: PMC5347939.
 15. Kumar N, Prasad K, Ramanujam L, K R, Dexith J, Chauhan A. Evaluation of treatment outcome after impacted mandibular third molar surgery with the use of autologous platelet-rich fibrin: a randomized controlled clinical study. *J Oral Maxillofac Surg* 2015;73:1042-9
 16. Bao M, Du G, Zhang Y, Ma P, Cao Y, Li C. Application of Platelet-Rich Fibrin Derivatives for Mandibular Third Molar Extraction Related Post-Operative Sequelae: A Systematic Review and Network Meta-Analysis. *J Oral Maxillofac Surg*. 2021 Dec;79(12):2421-2432. doi: 10.1016/j.joms.2021.07.006. Epub 2021 Jul 13. PMID: 34403654.
 17. Chitsazi MT, Dehghani AH, Babaloo AR, Amini S, Kokabi H. Radiographic comparison of density and height of posterior maxillary bone after open sinus lift surgery with and without PRF. *J Adv Periodontol Implant Dent*. 2018 Dec 25;10(2):43-49. doi: 10.15171/japid.2018.008. PMID: 35919893; PMCID: PMC9327569.
 18. Nevins ML, Camelo M, Schupbach P, Kim DM, Camelo JM, Nevins M. Human histologic evaluation of mineralized collagen bone substitute and recombinant platelet-derived growth factor-BB to create bone for implant placement in extraction socket defects at 4 and 6 months: a case series. *Int J Periodontics Restorative Dent*. 2009 Apr;29(2):129-39. PMID: 19408475.
 19. A. Temmerman, J. Vandessel, A. Castro et al., "The use of leucocyte and platelet-rich fibrin in socket management and ridge preservation: a split-mouth, randomized, controlled clinical trial," *Journal of Clinical Periodontology*, vol. 43, no. 11, pp. 990–999, 2016.