

CORONECTOMY - AN ALTERNATIVE TO SURGICAL EXTRACTION OF DEEPLY IMPACTED MANDIBULAR THIRD MOLAR - A CASE REPORT

КОРОНЕКТОМИЈА - АЛТЕРНАТИВЕН ПРИСТАП НА ХИРУРШКА ЕКСТРАКЦИЈА НА ДЛАБОКО ИМПАКТИРАНИ МАНДИБУЛАРНИ ТРЕТИ МОЛАРИ - ПРИКАЗ НА СЛУЧАЈ

Kacarska M.

Department of oral surgery, Faculty of Dentistry, University, Ss. Cyril and Methodius", Skopje

Abstract

Deeply impacted mandibular third molars in close proximity to the inferior alveolar canal pose a therapeutic challenge. Difficult surgical removal may lead to temporary or permanent damage to the inferior alveolar nerve (IAN) resulting in paresthesia, hypoesthesia or dysesthesia of the lower lip, teeth, gingiva and skin over the chin, which significantly affects the patient's quality of life. Besides (also), the need to prevent these kinds of injuries is especially important since current treatment modalities of neurosensory deficit management show only limited improvement in sensation. Coronectomy is the oldest and the best researched of the IAN injury-risk reducing procedures. This procedure is designed to remove only the crown portion of the tooth, leaving the roots in situ, thus damage to the inferior alveolar nerve is minimized. The aim of this paper is to depict a case of coronectomy performed as an alternative approach to complex surgical removal of a deeply impacted mandibular third molar with inferior alveolar nerve involvement. Careful perioperative radiological assessment of root morphology and detection of radiological signs for mandibular canal involvement preceded the treatment decision. With number of roots vaguely established to four, apically dilacerated, superimposed and extended beyond the lower rim of the mandibular canal the assumption of complex surgical removal of the impacted third molar with abundant bone loss, root fractures and inferior alveolar nerve injury was made. Coronectomy was considered to avoid major surgical trauma and to minimize the risk of inferior alveolar nerve injury. Under local infiltrative anesthesia, triangular flap was raised and pericoronar osteotomy was made, followed by transversal section of the crown at the cement-enamel junction. The crown was detached and removed, and the residual surface was trimmed. The wound was thoroughly cleaned and sutured. The postoperative period was uneventful. No signs of sensitive disturbances in the left mandibular side were noted. **Key words:** impacted mandibular third molar, coronectomy

Апстракт

Мандибуларните трети молари кои се длабоко импактирани и во непосредна близина на инфериорниот алвеоларен канал претставуваат терапевтски предизвик. Тешкото хируршко остранување може да доведе до привремено или трајно оштетување на инфериорниот алвеоларен нерв (ИАН), резултирајќи со парестезија, хипоестезија или дизестезија на долната усна, забите, гингивата и кожата на брадата, состојби кои значајно влијаат на квалитетот на животот. Покрај тоа, потребата од превенција на овој вид на повреда е исто така особено важна бидејќи актуелните терапевтски модалитети на неуросенитивен дефицит покажуваат само делумно подобрување во осетливоста. Коронектомијата претставува најстара и најдобро проучена процедура за намалување на ризикот од оштетување на инфериорниот алвеоларен нерв. Оваа процедура е дизајнирана така да се отстранува само коронарниот дел на забот, додека корените се оставаат in situ, со што се намалува ризикот од повреда на инфериорниот алвеоларен нерв. Целта на овој труд беше да прикаже случај на коронектомија изведена како алтернатива на комплексната хируршка екстракција на мандибуларен трет молар импактиран длабоко и во непосредна близина на инфериорниот алвеоларен нерв. На одлуката за видот на третманот и претходеше внимателна предоперативна рентгенолошка проценка на коренската морфологија и детекција на рентгенолошките знаци за инволвираност на мандибуларниот канал. По провизорно утврдување на бројот на корените на четири, апикално повиени, совпаднати и протегнати под долната ивица на мандибуларниот канал, се претпостави комплексно хируршко отстранување на импактираниот трет молар со обемен коскен губиток, фрактура на корените и повреда на инфериорниот алвеоларен нерв. Коронектомија беше земена предвид со цел да се избегне значителна хируршка траума и да се намали ризикот од повреда на инфериорниот алвеоларен нерв. Под локална инфилтративна анестезија и формиран триаглест флап, се направи перикоронарна остеотомија и попречна секција на коронката на ниво на емајлово-цементната граница. По ослободување, коронката се отстрани, а останатата површина се израмни. Раната се исчисти и сутурира. Постоперативниот период беше спокоен. Не беа забележани знаци на сетилно нарушување на левата мандибуларна страна. **Клучни зборови:** импактиран мандибуларен трет молар, коронектомија.

Introduction

Mandibular third molars are the most frequently impacted permanent teeth. Newly published evidence suggested that 72,2% of the entire world's population has at least one impacted tooth (usually lower third molar)^{1,2,3,4}. Those associated with insufficient eruption space, recurrent pericoronitis, or advanced dental caries are deemed to be removed. Removal of impacted third molars is the most frequently performed surgery, compromising 30% of all operations⁵. Postoperative complications are highly related with the depth and position of impaction (i.e., mesio-angular, horizontal, vertical, and disto-angular), and the proximity to important anatomical structures such as the inferior alveolar nerve (IAN) canal⁶.

However, the most concerning postoperative complication is temporary or permanent damage to the inferior alveolar nerve (IAN) resulting in paresthesia, hypoesthesia or dysesthesia of the lower lip, teeth, gingiva and skin over the chin, which significantly affects the quality of life of the patient³. Ahmed C et al., reports that the common risk factors for the IAN damage includes advanced age and difficult impaction, but the most important one is the proximity of the root to the IAN canal⁷. The incidence of IAN damage varies from temporary paresthesia up to 8.1% and permanent discomfort up to 3.6%⁸. The risk of injury increases manifold, when the third molar root overlaps the nerve canal as identified by the radiographic imaging⁹.

The need to prevent these kinds of injuries is especially important since current treatment modalities of neurosensory deficit management show only limited improvement in sensation¹⁰. According to studies, complete recovery is uncommon with all types of available treatments^{10, 5}.

Therefore, prevention instead of cure. Various approaches have been proposed to decrease damage to the IAN in high risk cases, which comprise coronectomy and leaving the roots behind, staged surgical removal of the third molar¹¹, modified coronectomy and grafting¹², orthodontic aided extrusion¹³ and pericoronal osteotomy¹⁴.

Coronectomy is the oldest and the best researched of the IAN injury-risk reducing procedures¹⁵⁻²³. First described in 1984 by Ecuyer and Debien²³, this procedure is designed to reduce the risk of IAN injury by removing the crown portion of the tooth only, leaving the root in situ¹⁰. It has been listed as a standard treatment option for surgical management of third molars by the American association of oral and maxillofacial surgeons (AAOMS)²⁴. In spite of numerous studies supporting the effectiveness of coronectomy, the procedure

remains controversial due to the possibilities of infection and other odontogenic pathology arising from the roots left behind⁹.

The aim of this paper is to depict a case of coronectomy as an alternative approach to complex surgical removal of deeply impacted mandibular third molar with mandibular inferior alveolar nerve involvement.

Clinical report

A 42-year-old female patient was referred to the University department of oral surgery for removal of an unerupted tooth in the lower jaw due to the need for lower denture. She didn't have any complaints regarding the tooth in question. The patient was in good general health, without any co-morbidities. Clinical examination revealed continued mandibular front, from right premolar to left first molar. In the most posterior aspect of the left mandibular quadrant, a semilunar split in the attached gingiva was evident (figure 1).

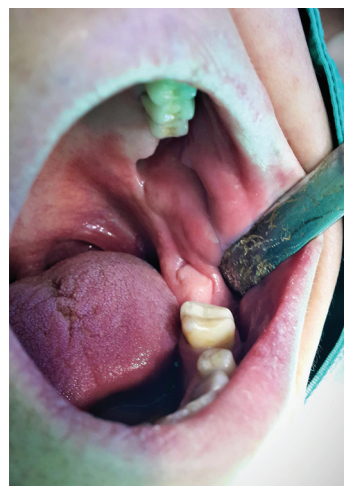

Figure 1. Intraoral view of the left posterior mandibular quadrant with semilunar split in the crestal aspect of attached gingiva with normal color.

On probing, the hard enamel of the mandibular left third molar was reached. Patient's orthopantomogram depicted a deeply impacted mandibular third molar (class C according to Pell and Gregory's classification), with mesioangular angulation according to Winter's classification. Careful perioperative radiological assessment of root morphology and detection of radiological signs for mandibular canal involvement preceded the treatment decision. The number of roots was vaguely established to four: two mesial and two distal, apically dilacerated, superimposed and extended beyond the lower rim of the inferior alveolar canal. Even more important is that the radiopaque superior border of the canal was interrupted in the bifurcation area (figure 2).

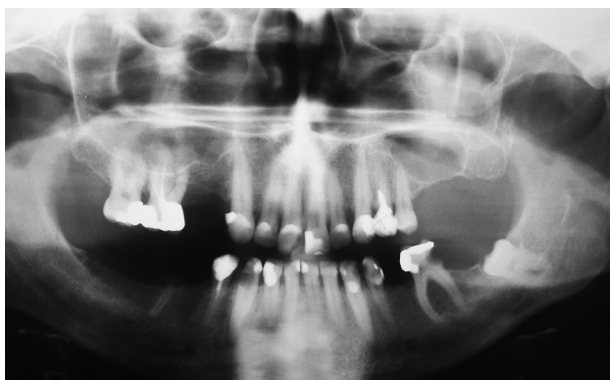

Figure 2. Patient's orthopantomogram depicted deeply impacted left mandibular third molar with multipart root complex superimposed and extended beyond the lower rim of the mandibular canal

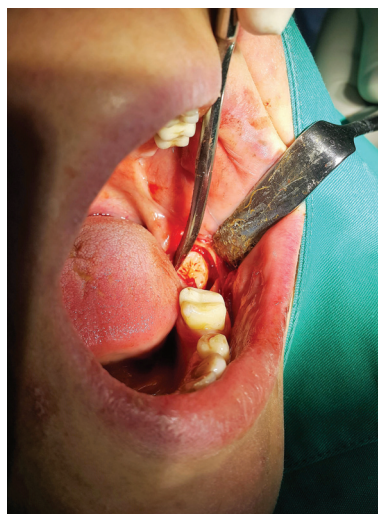

Figure 5. Peri coronary bone removed to the cemento-enamel junction

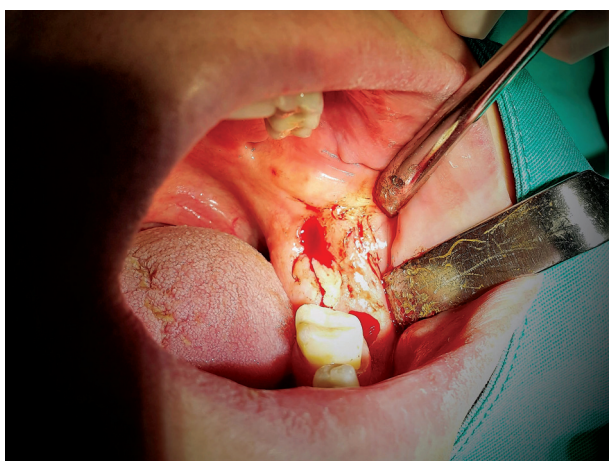

Figure 3. Triangular flap extended medially

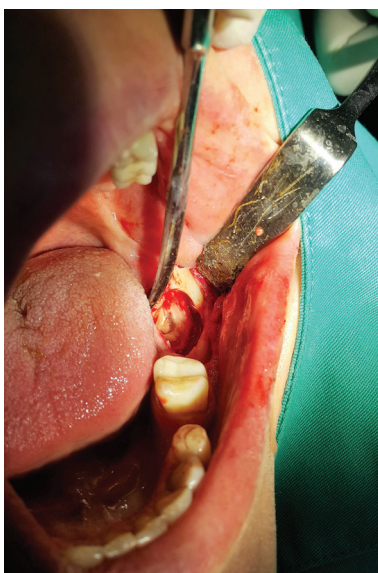

Figure 6. Transversal section of the crown

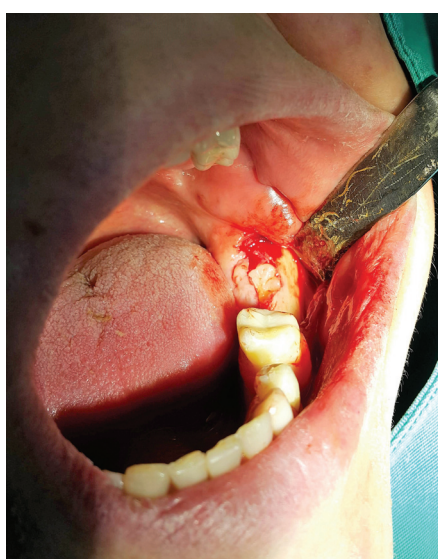


Figure 4. Retracted flap exposing the crown imbedded in cortical bone

After root morphology proximately established, and radiological signs of interest detected, the assumption of complex surgical removal with abundant bone loss, root fractures and inferior alveolar nerve injury was made. To avoid significant surgical trauma and to minimize the risk of inferior alveolar nerve injury, coronectomy was taken into consideration.

With the patient's concurrence, the coronectomy was planned in the following manner. Under local infiltrative block anesthesia of n.alveolaris inferior, n.lingualis and n.buccalis with 2% mepivacaine cum epinephrine (Scandonest 2% with epinephrine, Septodont – France) a triangular flap was positioned (figure 3) with a scalpel No.15 (Aesculap, Tutingen Tuttlingen, Germany).

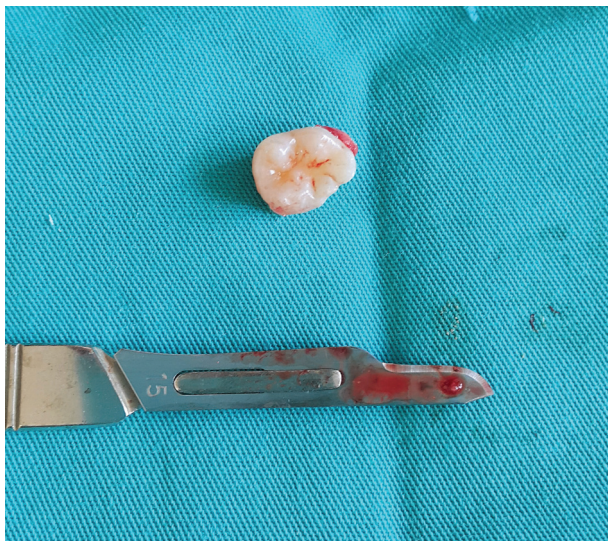

Figure 7. Detached crown on the surgical table

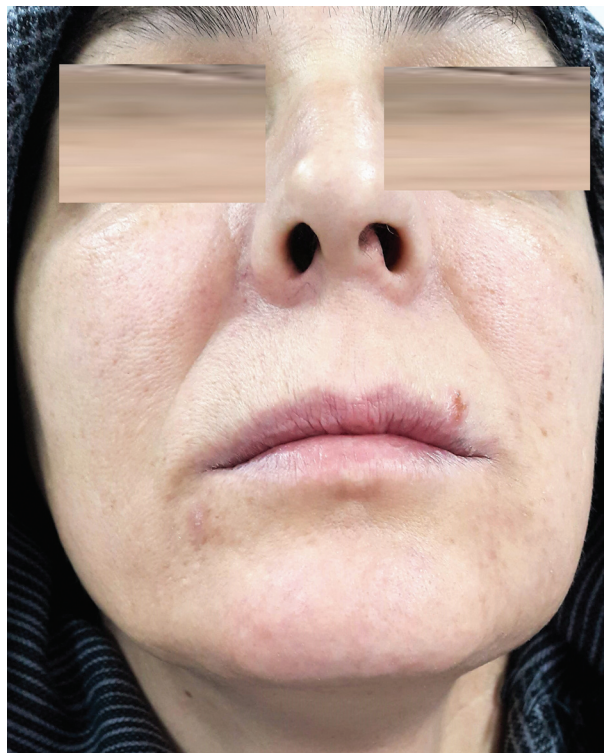

Figure 9. Postoperative extraoral appearance without swelling and skin discoloration

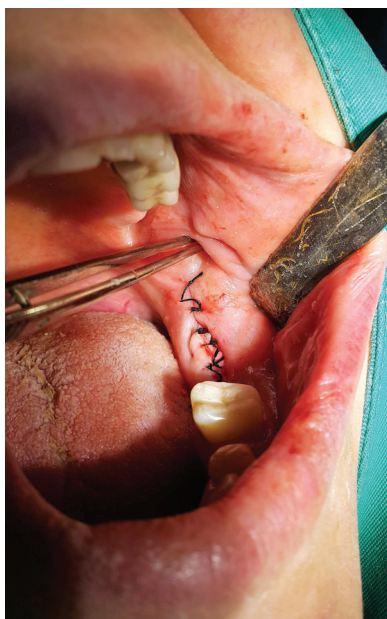

Figure 8.
Surgical
wound with
sutures

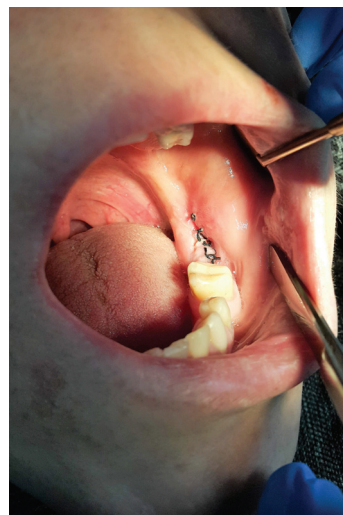


Figure 10. Wound
healing by secondary
intention

Peri coronary osteotomy with carbide round bur was executed, down to the cement-enamel junction, followed by transversal sectioning of the crown with carbide fissure bur under copious irrigation (figures 5 and 6). The crown was then detached (figure 7) and the remaining surface trimmed.

The wound was thoroughly cleaned from any debris. Finally, the wound's margins were reapproximated with interspersed sutures (figure 8).

The patient was advised to follow standard post-surgery recommendations. On the following day the patient was asymptomatic, without pain, swelling or discoloration (figures 9 and 10). Sutures were removed seven days post-op, and the extraoral and intraoral appearance remained as usual.

oration (figures 9 and 10). Sutures were removed seven days post-op, and the extraoral and intraoral appearance remained as usual.

Discussion and conclusion

Surgery of impacted mandibular third molars depends on the pre-operative findings. Pre-operative assessment

must be carried out radiologically in an effort to identify the proximity of the impacted tooth to the inferior alveolar canal²⁵. Usually, surgical extractions of impacted teeth are planned in accordance with panoramic findings. Especially, when treatment of deep impactions lays ahead, it is vital to know that panoramic radiographs are reliable in assessing the proximity of impacted mandibular third molars to inferior alveolar canal²⁶. Certain radiological aspects are to be detected in order to predict whether a certain clinical situation poses a risk for IAN damage. Rood and Shehab tested the predictive ability of IAN injury according to panoramic radiography with seven radiological parameters to be root-related, such as: root darkening, root diversion (deflection), root narrowing and root splitting. The additional three radiological parameters they considered to be canal-associated, such as: loss of continuity of the upper border of the mandibular canal, canal deflection and narrowing of the canal. Their research pointed out a significant correlation between the following radiological parameters and the possibility of a nerve damage following surgical treatment in lower third molars: canal deflection, root darkening and loss of continuity of canal borders. They concluded that other parameters are of no significance. Mesioangular impactions are closer to inferior alveolar canal and interruption of the white line is the most reliable risk predictor sign on the panoramic radiographs⁹.

The meticulous pre-operative radiological examination in the presented case showed medially angulated and deeply impacted left third molar, with complex root morphology, likely four split and diverse roots that superimposed and extended beyond the lower rim of the mandibular canal. Those are very strong radiological risk predictors per se. As mentioned before, the risk of injury increases manifold, when the third molar root overlaps the nerve canal as identified by the radiographic imaging⁹. Additionally, there was loss of the radiopaque superior border of the mandibular canal in the vicinity of the bifurcation area of the third molar. Such radiological parameters were indicative of alveolar nerve injury if surgical extraction was undertaken. Other radiological diagnostic methods might be beneficial in case of surgical extraction, such as cone beam computer tomography (CBCT). However, with the immensity of bone loss remaining the same during the surgical extraction with CBCT, such investigation was deemed unnecessary, expensive and was not pursued. Bone preservation is an essential surgical principal in all oral surgery procedures. In the presented case, the stabilization of the lower denture relied solely on the firm bony fundament. Therefore, the objective was to avoid significant surgical trauma and to minimize the risk of inferior alveolar

nerve injury. There are certain ways to perform a coronectomy. Landi L et al. recommends coronectomy to be done 2mm-3mm from the occlusal surface without involving the pulp after considering the pulpal anatomy of the impacted third molar tooth and the distance between the third molar crown and the second molar¹¹. In case of accidental pulpal exposure, pulpal dressing or pulpotomy was advised. In the presented case, the crown was sectioned at the level of cemento enamel junction, and the remaining enamel was grinded off 2-3 mm below the alveolar crest. It was described that the enamel is inert, and soft tissue cannot attach to its surface therefore the socket does not heal²⁷. It acts as a foreign body, so chances of infection of the unhealed socket are higher. Root fragment at least 3 mm inferior to the crest of bone seems appropriate and appears to encourage bone formation over the retained root fragment²⁸⁻³⁰. The roots were to be left behind and aim for osseocementum formation over the retained root, in contrast to migration and staged removal protocol of Landi L et al¹¹. After the coronectomy, the pulp was exposed without visible bleeding. Treatment attempts were not considered in concurrence with O'Riordan et al⁸. Coronectomy decompresses the pulp chamber, thus it will not be a significant contributing factor for post-operative pain. Histological evaluation of the retrieved lower third molar roots stated that symptoms after coronectomy do not result from the loss of pulp vitality or subsequent periradicular inflammation. It was refined that these pulpal tissues blend with overlying connective tissue when the mucosa heals successfully and the opening of the canal heals with osteo-cementum²⁷. As a curiosity, it was described that pulpal treatment of the retained root has resulted in high rate of infection and the subsequent need for removal³¹. Retention of root after coronectomy is based on the idea that broken fragments of vital teeth generally heal without complications^{32,33}, and ³⁴. This procedure attracted special attention in the last decade, because of the reported benefits and success rate of this technique, in contrast to the contemporary belief that the roots left behind will be source of problems^{11,35}, and³⁶. Not all third molars are suitable for coronectomy. Those with infection and mobility should be excluded, because remnants of those teeth may act as foreign bodies. In addition, teeth that are horizontally impacted along the course of the inferior alveolar canal may be unsuitable, because the sectioning of a tooth could endanger the nerve¹⁵.

Although some authors used preoperative prophylactic antibiotic therapy or suggested post-operative use¹⁷, no such protocol was followed in this case and no infection emerged. The coronectomy performed on an intact third molar in a healthy individual was not an indication for

antibiotic prophylaxis of local inflammation. It is the author's firm belief that prudent antibiotic use is indispensable to fight antibiotic resistance.

In spite of the reported advantages, patients are very anxious about leaving the root behind in the bone and are not willing to take a chance for infection or a second surgical intervention. The surgeon is responsible for informing the patient to her/his best abilities concerning the proposed treatment, and to gain their trust.

The disadvantages of coronectomy include deep periodontal pockets on the distal of the second molars (similar to those after extractions in comparable circumstances), root migration with the possible need of a second procedure, dry sockets, local post-operative infections, post-operative pain and inadvertent root removal, or root walk-out during surgery which may increase the risk of IAN injury, also known as a failed coronectomy^{15, 16, 8, 37}. The second molar was absent so there was no reason for periodontal concern. Post-operative period was uneventful, without pain, or infection. And last, but not least, no signs of sensitive disturbances in the left mandibular side were noted. It is not necessary to recall the patient after 6 months, unless the patient becomes symptomatic¹⁵, which was not the case.

Conclusion

Coronectomy may be a suitable alternative to complex surgical extraction of impacted mandibular molars with no infection and in close proximity to the mandibular canal, as shown on the panoramic radiograph. Every patient is unique, every situation is special and in carefully selected cases the most conservative surgical approach is the appropriate one.

Reference

1. Motamedi K, Hosein M. A Textbook of Advanced Oral and Maxillofacial Surgery Complications Following Surgery of Impacted Teeth and Their Management. 2013
2. Divya T, Themozhi MS. Third molar impaction- a review. J Pharm Sci Res. 2014;6(11):363–367.
3. Juodzbalsys G, Daugela P. Mandibular third molar impaction: review of literature and a proposal of a classification. J Oral Maxillofac Res. 2013;4(2):1-12.
4. Popli G, Kiran D.N, Iyer N, Sethi S, Bansal V, Bansal A. Influence of Pederson score and its constitutional anatomical parameters to predict the postoperative morbidity after Lower Third Molar Removal: a prospective cohort study. Am J Oral Maxillofac Surg. 2014;2(1):7–14.
5. Alantar A, Roisin-Chausson MH, Commissionat Y, et al. Retention of third molar roots to prevent damage to the inferior alveolar nerve. Oral Surgery, Oral Medicine, Oral Pathology, Oral Radiology 1995;80(2):p126.
6. Vafaei N, Ferretti C. Coronectomy: an alternative therapy for the symptomatic, impacted third molar report of 9 cases. Scientific. 2008;22:34:6-12.
7. Ahmed C, Wafae el W, Bouchra T. Coronectomy of third molar: a reduced risk technique for inferior alveolar nerve damage. Dent Update. 2011;38:267–76.
8. O'riordan BC. Coronectomy (intentional partial odontectomy of lower third molars) Oral Surg Oral Med Oral Pathol Oral Radiol Endod. 2004;98(3):274–280.
9. Mukherjee S, Vikram B, Sankar D, Veerabahu MS. Evaluation of outcome following coronectomy for the management of mandibular third molars in close proximity to the inferior alveolar nerve. J.Clinical Diagnosis Res. 2016 Aug; 10(8):57-62.
10. Leung YY, Fung PPL, Cheung LK. Treatment modalities of neurosensory deficit after lower third molar surgery: a systematic review. Journal of Oral and Maxillofacial Surgery. 2012;70(4):768–778.
11. Landi L, Manicone PF, Piccinelli S, Raia A, Raia R. A novel surgical approach to impacted mandibular third molars to reduce the risk of paresthesia. J Oral Maxillofac Surg. 2010;68:969–74.
12. Leizerovitz M, Leizerovitz O. Modified and grafted coronectomy: A new technique and a case report with twoyear followup. Case Rep Dent. 2013.
13. Alessandri Bonetti G, Bendandi M, Laino L, Checchi V, Checchi L. Orthodontic extraction: Riskless extraction of impacted lower third molars close to the mandibular canal. J Oral Maxillofac Surg. 2007;65(12):2580–86.
14. Tolstunov L. Pericoronary ostectomy as alternative treatment option for extraction of impacted mandibular third molars in proximity to inferior alveolar nerve. J Oral Maxillofac Surg. 2010;68(1):231–32.
15. Pogrel MA, Lee JS, Muff DF. Coronectomy: a technique to protect the inferior alveolar nerve. Journal of Oral and Maxillofacial Surgery. 2004;62(12):1447–1452.
16. Renton T, Hankins M, Sproate C, McGurk M. A randomised controlled clinical trial to compare the incidence of injury to the inferior alveolar nerve as a result of coronectomy and removal of mandibular third molars. British Journal of Oral and Maxillofacial Surgery. 2005;43(1):7–12.
17. Pogrel MA. An update on coronectomy. Journal of Oral and Maxillofacial Surgery. 2009;67(8):1782–1783.
18. Leung YY, Cheung LK. Safety of coronectomy versus excision of wisdom teeth: a randomized controlled trial. Oral Surgery, Oral Medicine, Oral Pathology, Oral Radiology and Endodontology. 2009;108(6):821–827.
19. Hatano Y, Kurita K, Kuroiwa Y, Yuasa H, Ariji E. clinical evaluations of coronectomy (intentional partial odontectomy) for mandibular third molars using dental computed tomography: a case-control study. Journal of Oral and Maxillofacial Surgery. 2009;67(9):1806–1814.
20. Dolanmaz D, Yildirim G, Isik K, Kucuk K, Ozturk A. A preferable technique for protecting the inferior alveolar nerve: coronectomy. Journal of Oral and Maxillofacial Surgery. 2009;67(6):1234–1238.
21. Cilasun U, Yildirim T, Guzeldemir E, Pektas ZO. Coronectomy in patients with high risk of inferior alveolar nerve injury diagnosed by computed tomography. Journal of Oral and Maxillofacial Surgery. 2011;69(6):1557–1561.
22. Leung YY, Cheung LK. Coronectomy of the lower third molar is safe within the first 3 years. Journal of Oral and Maxillofacial Surgery. 2012;70(7):1515–1522.
23. Ecuyer J, Debien J. Surgical deductions. Actualites Odonto Stomatologiques. 1984;38(148):695–702.
24. Liebllich SE, Kleiman MA, Zak MJ J. Parameters of care: clinical practice. Guidelines for oral and maxillofacial surgery. (AAOMS Par Care 2012) Journal of Oral and Maxillofacial Surgery. 2012;70 (e50).
25. Rood JP, Shehab BA (1990) The radiological prediction of inferior alveolar nerve injury during third molar surgery. Br J Oral

-
- Maxillofac Surg 28(1): 20–25.
26. Deshpande P, Guledgud M, Patil K. Proximity of impacted mandibular third molars to the inferior alveolar canal and its radiographic predictors: A panoramic radiographic study. *J. Maxillofacial surgery*. 2013;Jan; 12(2): 145-151.
 27. Patel V, Sproat C, Kwok J, Beneng K, Thavaraj S, McGurk M. Histological evaluation of mandibular third molar roots retrieved after coronectomy. *Br J Oral Maxillofac Surg*. 2014;52:415–19.
 28. Johnson DL, Kelly JF, Flinton RJ, Cornell MT. Histological evaluation of vital root retention. *J Oral Surg*. 1974;32(11):829–33.
 29. Whitaker DD, Shankle RJ. A study of the histologic reaction of submerged root segments. *Oral Surg Oral Med Oral Pathol*. 1974;37:919–35.
 30. Plata R L, Kelln E E, Linda L. Intentional retention of vital submerged roots in dogs. *Oral Surg Oral Med Oral Pathol*. 1976;42:100–08.
 31. Sencimen M, Ortakoglu K, Aydin C, Aydintug YS, Ozyigit A, Ozen T, et al. Is endodontic treatment necessary during coronectomy procedure? *J Oral Maxillofac Surg*. 2010;68:2385–90.
 32. Fareed K, Khayat R, Salins P. Vital root retention: A clinical procedure. *J Prosthet Dent*. 1989;62(4):430–34.
 33. Knutsson K, Lysell L, Rohlin M. Post-operative status after partial removal of the mandibular third molar. *Swed Dent J*. 1989;13(1-2):15–22.
 34. Velickovski B, Peeva M, Velevska D, Kacarska M: Coronectomy-prevention from the injury of the Inferior alveolar nerve (n.alveolaris inferior). *International Journal of case reports*, vol.5, 2015, No 14.
 35. Umar G, Obisesan O, Bryant C, Rood JP. Elimination of permanent injuries to the inferior alveolar nerve following surgical intervention of the "high risk" third molar. *Br J Oral Maxillofac Surg*. 2013;51(4):353–57.
 36. Goto S, Kurita K, Kuroiwa Y, Hatano Y, Kohara K, Izumi M, et al. Clinical and dental computed tomographic evaluation 1 year after coronectomy. *J Oral Maxillofac Surg*. 2012;70:1023–29
 37. Tolstunov L, Javid B, Keyes L, Nattestad A. Pericoronectomy: an alternative surgical technique for management of mandibular third molars in close proximity to the inferior alveolar nerve. *Journal of Oral and Maxillofacial Surgery*. 2011;69(7):1858–1866.